

Equine Endometrial Biopsies

Background

Histological examination of endometrial biopsies constitutes an important part of a breeding soundness examination (BSE). The histological examination detects and quantifies inflammatory and degenerative changes to the endometrium, and these findings, together with information obtained from other aspects of the breeding soundness examination, can help in the diagnosis of uterine disease, and help to predict the likelihood of a mare conceiving, and carrying a pregnancy to term.

Technique and submission

It is important that a lack of pregnancy is confirmed before endometrial biopsy is carried out. The technique may be carried out at any stage of the oestrus cycle, although dioestrus is preferred (1). Detailed descriptions of the biopsy technique may be found in published papers and texts (2). Routine fixation in formalin is adequate; if using Bouin's fixative please note that the tissue should be removed within 24 h and transferred to either 70% alcohol or 10% formalin to prevent over-hardening of the tissue (please note that we do not keep or supply Bouin's fixative, and if using this fixative you should be aware of the particular health and safety precautions which apply) (3). Careful handling of the specimen is important to prevent artefactual tissue damage (for example upon removal from the biopsy forceps). If not already carried out, the jaws of the biopsy instrument may be swabbed using a sterile fine tipped swab to be submitted for bacterial culture.

A full history should be supplied, including results of any other parts of the BSE, past breeding history, and the stage of the oestrus cycle at the time of biopsy. This information will greatly aid in histological interpretation.

What information can be gained?

Examination of H&E stained sections is carried out to determine the presence, type and degree of any inflammation. Degenerative changes are also assessed, and include fibrosis, glandular dilation / cyst formation, glandular necrosis, and 'nesting' of endometrial glands, characterised by grouping of glands surrounded by fibrosis. In some cases special stains may be used to help visualise certain features (e.g. stains to highlight fibrosis, stains to identify bacteria). On the basis of these changes, a grade is assigned, which gives important information on the chances of conception and carriage of a foal to term.

Additional findings are described and discussed, examples include types of inflammatory cells and their potential significance, and the presence, morphology and staining characteristics of any potential aetiological agents.

Histological grading of endometrial biopsies

On the basis of histological changes, the endometrial biopsy is categorised as laid out below (known as the modified Kenney-Doig system (4)):

Grade I: Considered to have normal endometrium or mild, focal inflammation or fibrosis. Chance of conceiving and maintaining until term is greater than 80%.

Grade IIA: Mild to moderate inflammation and/or multifocal fibrosis with 1-3 layers of fibroblasts surrounding glands or < 2 fibrotic nests per 5 mm linear field. Endometrial atrophy in the late breeding season. Chance of conceiving and maintaining until term is 50-80%.

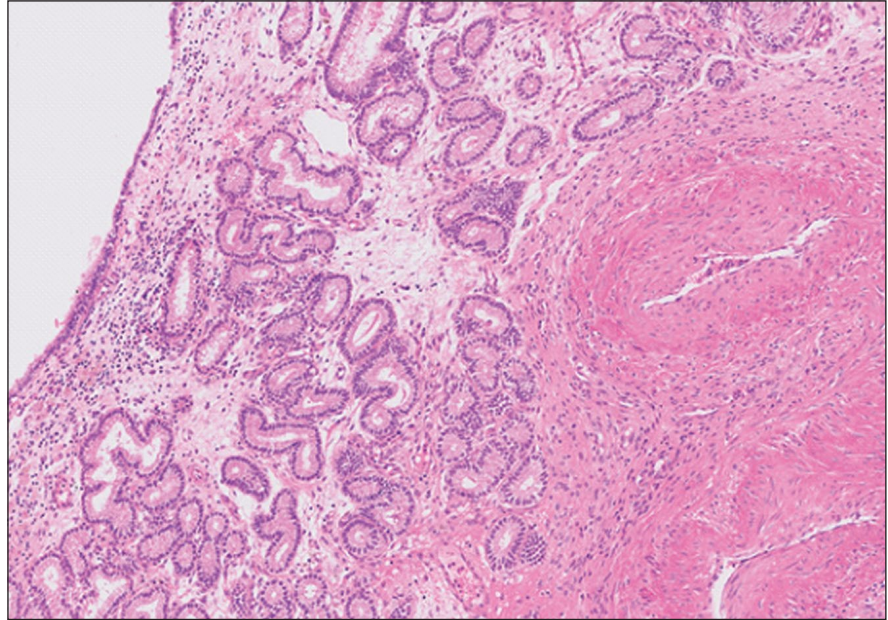
Grade IIB: Moderate inflammation and/or multifocal- diffuse fibrosis with 4 or more layers of fibroblasts surrounding glands or 2-4 fibrotic nests per 5 mm linear field. Chance of conceiving and maintaining until term is 10-50%.

Grade III: severe inflammation and/or diffuse fibrosis with 5 or more fibrotic nests per 5 mm linear field. Chance of conceiving and maintaining until term less than 10%.

(A history of barrenness for greater than 2 years increases the category to the next highest) (4) (3)

Limitations of endometrial biopsies

Note that many other factors will also influence conception and the maintenance of pregnancy. Clinical (e.g. uterine tone, conformational abnormalities), Ultrasonographical (e.g. follicular development, cyst formation, fluid accumulation), and microbiological (identification of potential pathogens) examinations all provide important information, and breeding management will have an influence on successful reproduction.



Endometrial biopsy showing stromal oedema and some mild fibrosis, with inflammation consisting of lymphocytes and macrophages. There is mild dilation of endometrial glands.

References

1. The Technique and Clinical Application of Endometrial Biopsy in the Mare. Ricketts, Sidney W. April 1975, Equine Veterinary Journal, Vol. 7, pp. 102-107.
2. Pinto, Carlos RF and Frazer, Grant S. Genital diseases, fertility and pregnancy. [ed.] Frank GR Taylor, Tim J Brazil and Mark H Hillyer. Diagnostic Techniques in Equine Medicine (2nd ed). s.l. : Elsevier, 2010, 7.
3. Equine endometrial biopsy reviewed: Observation, interpretation, and application of histopathologica data. Snider, TA, Sepoy, C and Holyoak, GR. 9, 2011, Theriogenology, Vol. 75, pp. 1567-1581.
4. Kenny, R M and Doig, P A. Current Therapy in Theriogenology. 2. Philadelphia : WB Saunders, 1986.

Axiom Veterinary Laboratories Ltd.

The Manor House • Brunel Road • Newton Abbot • Devon • TQ12 4PB
Tel: 01626 355655 • Fax: 01626 357750
admin@axiomvetlab.co.uk

